




Available online at
ScienceDirect
www.sciencedirect.com

Elsevier Masson France
EM|consulte
www.em-consulte.com/en



Technical Note

New innovative method relating guided surgery to dental implant placement



M.-A. Fauroux^{a,*}, M. De Boutray^b, E. Malthiéry^a, J.-H. Torres^a

^a Faculty of Dentistry, 545, avenue du Pr-J.L.-Viala, 34193 Montpellier cedex 5, France

^b Maxillofacial surgery Department, Hospital Center of Montpellier, 80, avenue Augustin-Fliche, 34090 Montpellier, France

ARTICLE INFO

Article history:

Received 18 September 2017

Accepted 13 February 2018

Available online 20 February 2018

Keywords:

Surgery

Computer-assisted/methods

Dental implantation

Endosseous/instrumentation

Dental implantation

Endosseous/methods

Computer-assisted design

ABSTRACT

Introduction: Companies selling dental implant guided systems mostly offer similar surgical guides. The purpose of this paper is to present an innovative-guided surgery system which originality lies in its guidance device, and to report the author's experience in using this system for dental implant surgery. **Technical protocol:** Two parallel tubes on either side of the drilling axis guide the successive drills and the implant placement. As a result of the lateral guidance, there is no friction of the drills on the surgical guide, which would damage it or contaminate the drilling hole with particles torn out from the guide. No radiological guide is needed during the radiographic examination stage. No successive diameter reduction tubes are requested. This guide can be used for all brands of implants.

Discussion: In our experience, 67 implants (31 titanium and 36 zircon implants) were placed in 35 patients with guided surgery system. Multiple clinical cases were treated with this system: 'one-stage' or a 'two-stage' surgical protocol, with flap and flapless surgical techniques, and with delayed or immediate loading. Clinical cases treated revealed good implant placement with planning. The widely open design of this guide allows irrigation and practitioner's sight control under conditions comparable to those of operations performed without surgical guide.

Conclusion: This dental implant guided system appears to be a significant advance in the field of implant surgical guides.

© 2018 Elsevier Masson SAS. All rights reserved.

1. Introduction

The use of guides in implant surgery is constantly increasing. This success is due to the service provided both to trainee practitioners (ensuring their surgical gesture) and to experienced clinicians (for whom guided surgery provides a reliable therapeutic solution in the case of complex implantations in which the accuracy of the implant positioning is crucial and may sometimes avoid pre-implant surgery). Of course, the use of these techniques is also interesting in the implant-supported rehabilitation by immediate 'loading'.

If the characteristics of the ideal guide had to be defined, first of all one would ask for precision: absence of defective manufacturing, a perfect fit in the mouth, high stability during the operation and optimal drill guide for a perfect reproducibility of the planning.

It is also necessary that the guide can be transported, stored and sterilized without any distortion or degradation. In addition, it is desirable that the design of the guide does not interfere with the visual inspection by the surgeon and with the drill irrigation. Finally, the use of this guide should not lead to a high increase in the cost of the operation. Companies selling dental implant guided systems offer surgical guides of similar design: they are dental, mucosa or bone supported, mostly made of resin, whereby drill holes are prepared within the body of the guide itself. These drill holes usually receive metal sleeves of various diameters to guide successive drills.

Having had the opportunity to test this innovative device, which differs significantly from the usual design, the authors wish to describe the system and the surgical protocol and to share their experience in their 35 clinical cases (67 implants).

2. Technical protocol

This technique required at least 3 clinical sessions, from the initial consultation to the surgical phase:

* Corresponding author.

E-mail addresses: marie-alix.fauroux@umontpellier.fr (M.-A. Fauroux), m-deboutray@chu-montpellier.fr (M. De Boutray), eve.malthiery@gmail.com (E. Malthiéry), jh.torres@umontpellier.fr (J.-H. Torres).

- initial consultation;
- impression, recordings of clinical parameters, radiology;
- surgical phase.

The number of sessions increased with the implementation of temporary prosthesis or prosthetic set up in case of complex edentulous jaws (but these steps were not related to the technique of guided surgery).

After the classic early stages of implantation (case study, guiding assembly and validation of prosthetic project) had been completed, clinical and radiographic parameters were collected. An impression of the edentulous dental arch was taken using a dental impression tray on which was attached a Lego® brick (Billund, Denmark), as stated in the protocol. At this stage, it was checked that the brick was placed within the exploration field of the X-ray image (the accuracy of repositioning the various clinical, optical and radiological data for planning depends on this device). By default, the brick was located in an anterior position on the dental impression tray (Fig. 1). In the case of a posterior edentulism, when using a radiographic exam of small field cone beam type, an additional brick was added to the dental impression tray in the implantation area. The impressions were made with a polyether-based material deemed sufficiently accurate and stable over time: Impregum® Penta® Soft (3M ESPE®, Pontoise, France), implemented with an automatic mixer: Pentamix® 3 (3M ESPE®, Pontoise, France). In the case of a totally edentulous patient, two blocks of auto-polymerizing resin were also fixed to the dental impression tray in the posterior area to ensure the immobility and the stability of the impression during X-ray exposure. The impression of the antagonist jaw was also taken using an alginate-based impression material, and then plaster casted.

During this preparatory phase, the maximum size of the mouth opening was recorded using several bricks stacked on top of one another on the dental impression tray. The top of the brick was connected to the antagonist teeth via a key made of auto-polymerizing resin. Auto-polymerizing resin was used, after spreading Vaseline on the antagonist teeth to facilitate the removal of the key.

The patient then went to X-ray (CBCT in this case) and was instructed to bite on the dental impression tray as an X-ray guide.

Following radiological acquisition, the digital files in DICOM format were loaded into an usual software and shared with the company that markets the guide (2ingis®, Belgium) via its secure Internet network. The quality of the images was then controlled by the radiographic visualization of the brick. The quality of digital data could be validated by the specific external and internal geometry of the plastic brick, clearly visible in X-ray: the lack of super-positioning of a standard scanner representation of a brick

with image of the brick included in the dental impression tray would identify any fault in the X-ray acquisition. After checking and validating the data, a brief study of the case was performed. If the bone quantity was considered sufficient, the practitioners were invited to submit the impression of the edentulous arch, the plaster model of the opposing arch, the pre-prosthetic wax up and the recordings of the clinical parameters (maximum mouth opening, inter arch relations) to the company, which carried out the digitization of these different elements through optical scanning. The practitioners also specified the brand of implants, which they intended to use, and the characteristics of the prosthetic project (as use of screw-retained prosthesis or cemented one, immediate loading...). All digital data were then integrated (STL format) in the planning software, where they were associated with imaging by super-positioning the images of the bricks. After planning of the positions, diameters, axis and sizes of implants by the clinicians, the company manufactured and shipped the individual patient surgical guides. The delay between sending the patterns and receiving the surgical guide was approximately about 3 weeks.

During the surgical phase, the specific surgical kit was used. It included a contra-angle with guide forks of different lengths (depending on the patient's capacity to open his or her mouth, the edentulous area and the depth of drilling). It also included depth wedges, a ring with two legs (to be inserted in the guide tubes in the same way as the drill guide fork) to guide the implant-holder during manual placement of the implant, a metal trephine to cut the gum, two zircon drills which respectively allow to flatten the bone crest and perform the initial drilling (pilot drill) (Fig. 2). Regular drills of the selected implant system were then used for the rest of the drilling sequence (using depth wedges if necessary). The practitioners followed the instruction sheet, which listed the drills needed throughout surgery. With the surgical guide remaining in place, the implants were inserted with the ratchet or the contra-angle.

This system was used by the authors to place 67 implants (36 zircon implants from Paris Implant® [Marnay, France] in ZIR-ROC clinical study, 23 titanium implants from Straumann® [Basel, Switzerland] and 8 titanium implants from Zimmer® [Florida, USA]) in 35 patients (28 patients for zircon implants and 7 patients for titanium implants). The clinical study has been conducted in full accordance with ethical principles. It was undertaken with the understanding and written consent of each patient and was independently reviewed and approved by the national ethics committee (2010-A00989-30/MS1). In the case where the edentulism was limited to three teeth, we used a small field cone beam device (Planmeca ProOne®, Helsinki, Finland). For more extensive edentulism or completely edentulous jaws, we used a wide-field CBCT device (NewTom 5G®, Verona, Italy). The insertions were

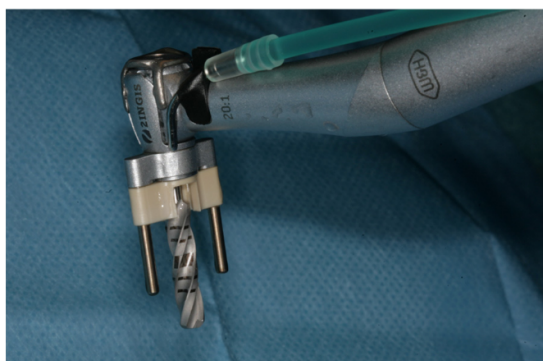

Fig. 1. Dental impression tray. As a spatial reference and a radiopaque marker, a Lego® brick is attached in the anterior position. In the posterior locations, auto-polymerizing resin wedges stabilize the impression tray during the CBCT exam.

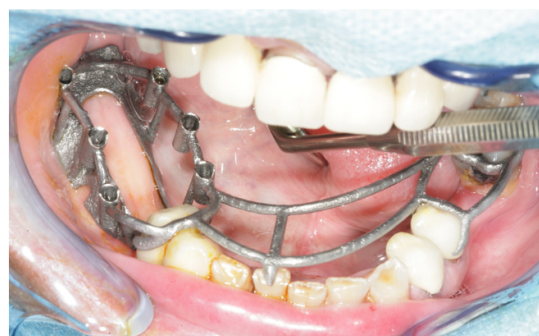

Fig. 2. Using the pilot zircon drill. A single implant was placed with this guide having thus only 2 twin tubes. Note that the guide was wider than appears on this picture, with stabilizer rods to connect it to lateral teeth.

performed according to a 'one-stage' or a 'two-stage' surgical protocol, with or without flapless surgery, and with delayed or immediate loading, depending on the prosthetic projects and surgical limitations of the clinical cases. The characteristics of the 35 clinical cases are reported Table 1. The guidance system was supported by a double tube (one on either side of the drilling axis). It consisted of the two parallel solid tubes integrated in the framework of the guide, into which the two legs of a fork attached to the head of the contra-angle can slide (Fig. 3). This system therefore contained as many pairs of guiding tubes as the number of implants to place. Successive drills were thus guided by these tubes. The penetration of the drills was controlled by the depth stop on the fork on the guide framework. If necessary, calibrated plastic wedges (Fig. 3) adapted to the fork were used to adjust the drill penetration and consequently determined the depth of drilling.

The manufacturing of the surgical guide used CAD-CAM technology. The design of the guide, customized for each individual patient (Fig. 4), was first worked out on a computer with a computer-aided design software. Different types of edentulisms (partial, interdental, total...) were treated (Table 1). The stability of the guide was sought out preferentially by dental supports. Bone support was required in cases of complete edentulism or if the dental supports were deemed unsatisfactory. After modeling, the surgical guide was printed by 'selective laser melting' of titanium powder. It was then sent to the practitioner for surgery with a 'surgical instruction sheet' showing the operating sequence including drills and wedges.

3. Discussion

The first specificity of the system lies in the use of a dental impression tray with a brick during the pre-operative phase. This technique eliminates the production of a radiological guide during the initial phase. In cases where the bone volume is considered insufficient after radiological analysis, which contraindicates the implant treatment, the extra cost of making a radiological guide (in addition to the cost related to imaging) does not benefit the patient. This additional cost is doubled when a pre-implant surgery is needed (since two radiological guides are requested: the initial one and the one made after the pre-implant surgery). In this system, the estimation of residual bone volume and its compatibility with the prosthetic project are evaluated in the planning phase, when no radiological guide is needed. The superposition of the brick images from different clinical and X-ray digital data seems to allow the association of these data with precision. The economy of time and resources is significant, without impairing the accuracy of the system.

Moreover, this new guidance system takes into account the extent of the patient's mouth opening, a pitfall that, when unknown, can compromise the placement of the implants. Indeed, limited mouth opening or excessive height of the surgical guide

can interfere with the drilling and cause an error in the drilling axis and can even make it impossible to use the surgical guide [1]. In this innovative system, the recording of the maximum mouth opening during the pre-operative phase and its integration to the planning allows validation of the possibility of using guided surgery, even before the radiographic acquisition (inspection of the required height for the insertion of the guide and the drills).

The second specificity of the system, and not the least, lies in the design of the surgical guide. This new concept with 2 tubes solves the problems found in other systems concerning irrigation, friction on the drills and visibility. The physiological importance of irrigation for any bone surgery and more specifically for implant drilling is well known [2]. In the systems where the guiding is wielded directly on the drill, the guide is inevitably an obstacle to irrigation and interferes with the cooling of the bone. On the contrary, the specific design of the present guide, widely open at the implantation site, makes the working area free of obstacles. Irrigation conditions are thus comparable to those of operations performed without surgical guide. This coaxial guide also allows the elimination of any friction of the drills on the guide. This suppresses any risk of wear to the drill and any damage to the guide, which would compromise its accuracy, or contaminate the drilling hole with the particles torn out from the surgical guide. Finally, freed from the need to enclose the drill to guide it, the surgical guide, widely open at the point of the drilling, does not impair the clinician's sight of the surgical field, which is a significant advantage compared to the central sleeve guides.

Regarding repositioning and stability of the guide during drilling, the system was very satisfactory. The titanium structure seems a good choice compared to resin structures, for reasons of strength and low distortion. As for the accuracy of manufacture, it can only be evaluated in the mouth when positioning the guide. The drills provided by the system are very well thought out. In most cases, we used the trephine to cut a gum pellet, in conditions of minimal invasiveness and to minimize postoperative troubles. For 'two time' surgical interventions, we felt that the design of the guide allows easy access to the edentulous crests for incisions and muco-periosteum flaps to be performed.

The process of flattening the bone crest in one attempt with a zircon drill before using the pilot drill seems to eliminate any risk of deviation of the drill on an oblique crest.

Compared with other systems, diameter reduction tubes are not required, which represents a time saving. All in all, the fact of not doing a flap and not having to change the guide between the various drills simplifies and shortens the surgical phase.

Due to its design, the system performs a strict guidance of the drilling without any looseness, neither in the drilling point on the crest nor on the drilling axis. In fact, once the fork is inserted into the tube axis, the drill has only a single degree of freedom, which is the drilling axis. The precision of the implant insertion benefits from the accuracy of this alignment. On the other hand, it proved difficult to take the contra-angle into the correct axis and enter the

Table 1
Characteristics of the clinical cases.

Number of patients	Age of patients	Number of implants placed per patients	Type of edentulism	Brand of implants	Material	Surgical protocol	With flap or flapless surgery	Delayed or immediate loading
28	28 to 77	1 or 2	Partial or interdental	Paris Implant	Zircon	One stage	Flapless	Delayed
2	65 to 74	8	Total	Straumann	Titanium	Two stage	Flap	Delayed
2	56 to 59	1	Partial	Straumann	Titanium	One stage	Flapless	Delayed
1	65	8	Total	Zimmer	Titanium	One stage	Flapless	Immediate
1	56	2	Partial	Straumann	Titanium	Two stage	Flap	Delayed
1	64	3	Partial	Straumann	Titanium	One stage	Flapless	Delayed



Fig. 3. The system of guidance attached on the contra-angle. The two legs of the fork are located on either side of the drilling axis. They can be inserted in the guide corresponding tubes. Optionally, a calibrated plastic wedge (white part) may be used to control the insertion depth.

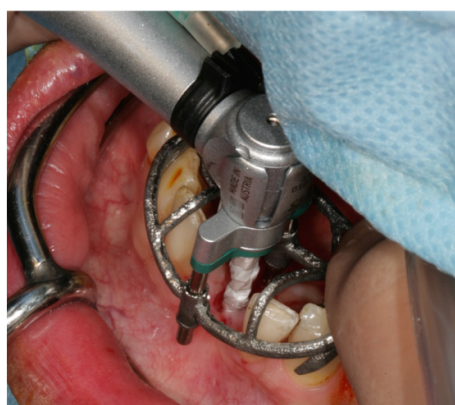


Fig. 4. The surgical guide, printed by 'selective laser melting' of titanium powder. Its personalized design features as many pairs of tubes as implants are to be placed (three in this case). Each pair of tubes will guide the two legs of the fork during drilling.

fork into the guide tubes. Finding this alignment appeared to be complex at the beginning. As with any new technique, a learning period was necessary for us to manage this system (1–2 interventions according to the practitioners). According to clinical and radiological post-surgery observations, no aberrant position nor immediate complication related to the positioning of the implants were found among the implants we placed. Fig. 5 shows a superposition with Meshlab[®] software from Italian National Research Council (ISTI, Italia) carried out to control pre-operative planning and clinical position of the implants.

Unlike some guidance systems in which the surgical procedure may be modified at any time by the surgeon [3], the clinician is forced here to respect and follow the parameters described during the planning stage. Although potentially frustrating to some surgeons, it has the advantage of ensuring the positioning of the implant precisely as it was planned. This reduces the chance of surgeon dependent variability, which can be very appreciated in clinical research studies.



Fig. 5. Visualization of the system accuracy. Superposition of the clinical position of the implants (purple objects) and pre-operative planning (brown cylinders). Image generated with Meshlab[®] software from ISTI (Italian National Research Council, Italia).

Another advantage of the system comes from the fact that the guidance is not exerted directly on the drill: this guide can therefore be used for all brands of implants. Drills of any design, including conical shaped drills, can be guided with the same precision without any problem.

The total expenditure is generated by acquiring the software, and by the planning and the construction of the guide. It depends on both the autonomy of the clinician (in creating a plan by him/herself or through the help of the company) and the number of implants to be placed (the cost increases with the number of pairs of guide tubes). Costs related to the use of this system can go up to 750 € for the purchase of the software (amount paid once), 50 to 480 € for the planning from 1 to 10 implants (not charged if the practitioner performs this step himself) and from 290 to 990 € for the manufacturing of the guide.

Throughout our observations, only one of these guides could not be adapted to the dental morphology, which forced us to postpone the procedure and wait for a new guide made from a new impression (the cause of this problem was probably a distortion of the initial impression). When compared to the benefits of this system, the time required for planning, manufacturing and shipping of the guide, as well as the additional costs of using the system seemed quite reasonable.

4. Conclusion

In conclusion, through its open framework and its distance guidance of the drill, the guide stands out from other systems and appears to be a significant advance in the field of implant surgical guides.

In all cases, the widely open design of this guide allowed irrigation and practitioner's sight control under conditions comparable to those of operations performed without surgical guide. There was no friction of the drills on the surgical guide, which would have damaged it or contaminated the drilling hole with particles torn out from the guide. Clinical case treated with immediate loading revealed good adaptation for the immediate prosthetic rehabilitation and the satisfaction of the patient.

Authors' contributions

M.-A. Fauroux: concept and design of clinical care/data collection/drafting article/final approval of the version to be published/agreement to be accountable for all aspects of the work.

M. De Boutray and E. Malthi ry: collection and interpretation of data/critical revision of the article/final approval of the version to be published/agreement to be accountable for all aspects.

J.-H. Torres: concept and design of clinical care/critical revision of article/approval of article/final approval of the version to be published/agreement to be accountable for all aspects.

Disclosure of interest

The authors declare that they have no competing interest.

Acknowledgments

The authors would like to thank Marita Nicolas and Jean-Marc Huibant for their valuable contribution.

References

- [1] Shneider D, Marquardt P, Zwhlen M, Jung RE. A systematic review on the accuracy and the clinical outcome of computer-guided template-based implant dentistry. *Clin Oral Impl Res* 2009;20(Suppl. 4):73–86.
- [2] Trisi P, Berardini M, Falco A, Podaliri Vulpiani M, Perfetti G. Insufficient irrigation induces peri-implant bone resorption: an in vivo histologic analysis in sheep. *Clin Oral Impl Res* 2014;25:696–701.
- [3] Armad S, Legac O, Galibourg A. Implantologie dentaire assist e par ordinateur : int r ts de la navigation du syst me Robodent . *Rev Stomatol Chir Maxillofac* 2013;114:247–54.